

Trigeminal Block for Submandibular Abscess in Pediatric with Difficult Intubation: A Case Report

Septian Adi Permana¹, Juan Cipta^{2*}

^{1,2} Staff of Anesthesiology and Intensive Therapy Departement Moewardi Hospital - Faculty of medicine, Universitas Sebelas Maret, Surakarta, Resident of Anesthesiology and Intensive Therapy Departement Moewardi Hospital – Faculty of medicine, Universitas Sebelas Maret, Surakarta

*Corresponding: juancipta@gmail.com

Received: 15 February 2024

Abstract

Background: The use of trigeminal block with/without ultrasonography guidance as a pain management in outpatient settings are common, mainly for neuralgic pain. Whereas, the use of trigeminal block are not widely performed intraoperatively especially for oral-maxillofacial surgery.

Case: We present a case of 16 year old boy diagnose with mandibular abscess prior to Open Reduction Internal Fixation (ORIF) due to mandibular fracture 1 months prior. Patient admitted with complaints of pain and swelling on right jaw, difficult opening his mouth and experienced a salty taste in mouth which we suspect the abscess penetrate into the oral cavity. Patient was in a limp condition, shortness of breath in supine position, with oxygen saturation of 96% room air. We use LEMON method to assess the intubation difficulties, we found swelling on the right jaw, Incisor distance less than 2 cm, make it impossible to evaluate mallampati score, and limited neck mobility due to pain. We decided to avoid general anesthesia since preoperative airway assessment indicates difficult intubation. We sedate the patient with midazolam and administered trigeminal block using 22-G needle with local anesthetic solution of levobupivacaine 0,375% and dexamethasone 2,5mg as an adjuvant with classic landmark trigeminal technique. The patient tolerated the procedure well and return to the ward after the procedure.

Conclusion: The use of trigeminal block can be as an alternative general anesthesia oral-maxillofacial surgery area that may have predisposing difficult airway intubation and may be valuable in contributing better patients outcomes.

Keywords: *Trigeminal nerve block, Mandibular abscess, Difficult intubation, Regional Anesthesia*

Introduction

The trigeminal nerve block is a simple technique that provides hemifacial anaesthesia by injecting local anesthetics to the branch of trigeminal nerve. This method have been shown to be effective for pain management in patients with trigeminal neuralgia and facial pain but never considered as an alternative to general anesthesia (GA).^{1,2} GA is used in modern-day medicine as a simple and relatively safe method to achieve surgical anesthesia. However, it is important to have alternative anesthesia in a limited environment or complicated patient condition such as patient with difficulty of intubation. Regional anesthesia may be given as an stress-free anesthesia, due to its simple technique, lower catecholamin release, decrease blood loss due to local vasoconstrictors and sympathetic blockade and lower risk of morbidity and complications with appropriate dose of local anesthetic (LA).³

Submandibular abscess is an infection of the deep neck space that may occur secondary to dental infection, gland sialadenitis, lymphadenitis, trauma or surgery. The mainstay of submandibular abscess consist of airway control, antibiotic medical treatment and surgical drainage (DNI). Surgical drainage may be complicated for these patients since airway obstruction are often found in consequence of anterior visceral space involvement. Anterior visceral space involvement occurred in association with an infection of both the submandibular and lateral pharyngeal space and may extend from hyoid bone down to the superior mediastinum. This space contains larynx, thyroid gland, trachea and cervical esophagus. Therefore, conventional endotracheal intubation and tracheotomy under general anesthesia may be problematic and a challenging task for anesthesiologist.⁴⁻⁶

One study showed that awake tracheotomy under local anesthesia, blind nasal intubation, and intravenous or gaseous induction followed by laryngoscopy and intubation are possible but not risk-free. However, there are no reported cases of using trigeminal block as an alternative for submandibular abscess patients with intubation difficulty.⁷ We report our experience with submandibular abscess pediatric patient who underwent incision and drainage surgery under trigeminal block with intravenous sedation.

Case

A 16-year-old boy patient was admitted with complaints of pain and swelling on right jaw with difficulty opening his mouth for the last 6 days, difficulty of breathing while sleeping for 5 days, bad taste in mouth and pus discharge for 3 days, that affect his food intake. The patient had a history of bilateral maxillary and mandibular internal fixation (ORIF) on September 23rd, 2023, due to mandibular fracture and found to have delayed wound healing and submandibular abscess. He was proposed for debridement and drainage on the submandibular abscess. On examination, the patient was on limp condition. His pulse rate was 110/min, regular rhythm and blood pressure measured in supine position was 100/80 mmHg. There was swelling on the right jaw (size 5cm x 5cm x 3cm) with redness and purulent discharge seen inside the mouth. Cardiovascular system examination and respiratory system showed normal but saturation on room air was 96%. We assessed the possibility of difficult intubation with LEMON, which we found swelling on right jaw, with pus discharge from previous mandibular ORIF; we evaluate the incisor distance, hyoid-mental distance, and thyroid to mouth distance (1-3-2); we cannot evaluate Mallampati score; we found submandibular abscess and limited neck mobility. From LEMON, we found that the patient has difficult airway, therefore it will be difficult to perform intubation.

His laboratory findings, ECG and Chest radiography are within normal limits. Cranial and Waters X-ray showed an internal fixation plate and screw in maxilla bone and mandibula with good alignment. Considering the risk of airway obstruction like inability to open the mouth and purulent discharge inside

the mouth, we decided to use trigeminal block with sedation for this patient.

Systole (mmHg)	102	98	96	100	92
Diastole (mmHg)	65	57	60	54	56
HR (bpm)	116	125	127	128	123
RR (/min)	23	23	25	22	21
SpO2 (%)	96	96	98	96	96
Time	17.00	17.15	17.30	17.45	18.00

Table 1. Hemodynamic during procedure

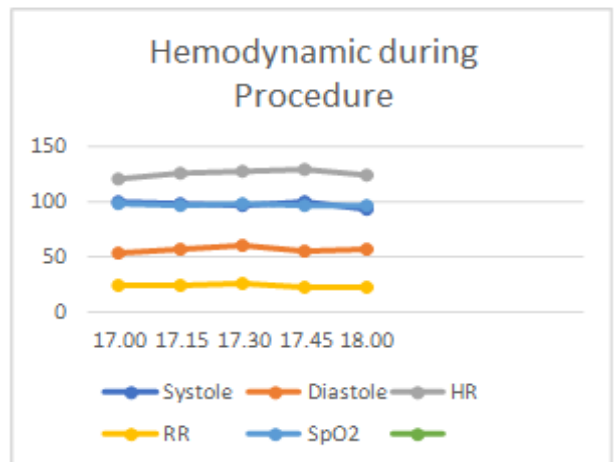


Figure 1. Hemodynamic during procedure

The patient was supine with head in neutral position and the eyes staring straight ahead. Intravenous sedation was given with midazolam 2 mg. We performed this trigeminal block using only submental and infraorbital nerve block. For submental block, we use the extraoral technique, mental foramen landmark, lie on a single line running about 2.5 cm lateral to the midfacial line and passing through the pupil, palpation of the mental foramen at the level of the second premolar. The skin over the cheek on the involved site was prepared with povidone-iodine and draped. A 22G, 50-mm long stimuplex needle was inserted into the mental foramen (Figure 2).

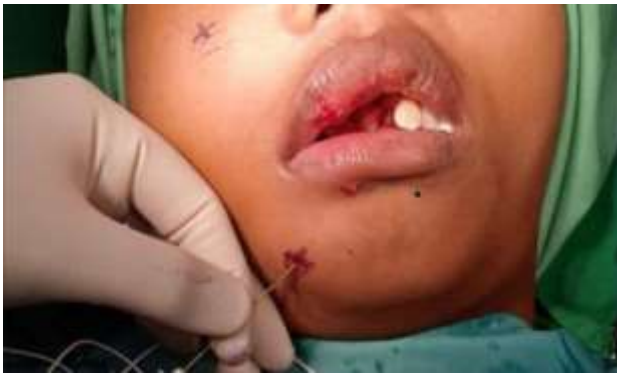

Figure 2. Mental Nerve Block⁸

For infraorbital nerve block, the end branch of the maxillary nerve, emerges about 1 cm below the middle of the lower orbital margin through the infraorbital foramen, Palpation of the infraorbital foramen, about 1 cm below the middle of the lower orbital margin. After palpating the infraorbital foramen, the needle is introduced cranially just below the palpation point until bone contact is made and then withdrawn slightly. (Figure 3). A solution of levobupivacaine 0,375% was used as a local anesthetic and dexamethasone 2,5mg as an adjuvant.

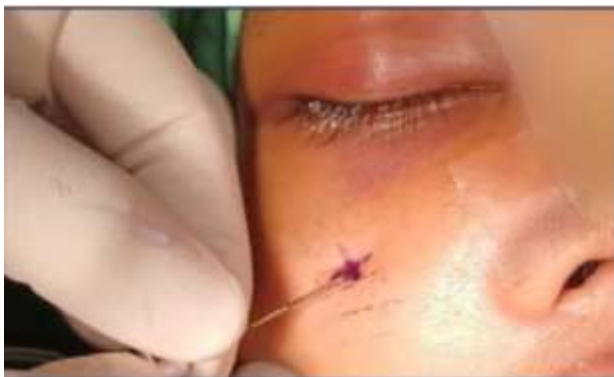

Figure 3. Infraorbital nerve block⁹

Patient was monitored all the time during surgery. Oxygen saturation was between 88 – 96% with nasal oxygen, blood pressure ranging from 92/52 mmHg to 100/65 mmHg, and heart rate between 110/bpm and 130/bpm. Patient tolerated well a standard debridement and pus culture procedure with no episodes of hypoxia and comfortable during surgery. Patient was planned to stay in PICU post operatively but had no indication of complication, therefore patients was transferred to general ward. Postoperatively pain was controlled with only paracetamol intravenous three times a day.

Discussion

Submandibular abscesses occur due to infections that can originate from oral mucosal infections, dental infections, submandibular salivary gland infection, blunt or penetrating trauma to the region, spread from adjacent space and complication from previous procedure upon the maxillofacial region.¹⁰ Management of submandibular abscess is commonly performed under general anesthesia; however, conventional endotracheal intubation and tracheotomy may be problematic, especially in patients experiencing difficulty opening their mouths.⁷ In our patient, we decided to avoid general anesthesia because difficulty to manage airway and perform intubation due to his inability to open mouth (only 2 cm-width). Therefore, we planned for regional anesthesia, and we picked trigeminal nerve block for the incision and drainage procedure.

Based on our literature review, we did not find the use of trigeminal block in submandibular abscess. However, we found trigeminal block had been utilized in serious cases such as orbital exenteration. Orbital exenteration was performed in 68-year-old man with many comorbid illness with 2 ml of lignocaine 2% and 5 ml of bupivacaine 0,5%.⁸ In a previous randomized controlled trial (RCT) involving patients undergoing faciomaxillary surgery, additional trigeminal nerve block significantly reduced pain scores, intraoperative and postoperative fentanyl requirements, and improved satisfaction scores compared to patients who only received general anesthesia (GA) management.¹¹ Other than trigeminal block, superficial cervical plexus block (SCPB) offers adequate regional anesthesia in the maxillofacial region as an alternative to GA due to its high success rate, low complications, higher acceptance of patients, and lower chances of morbidity and mortality.¹²

In trigeminal nerve block, local anesthetic solution is injected to the three superficial branches of the trigeminal nerve divisions: frontal nerve (of the ophthalmic nerve, V1 division); infraorbital nerve (of the maxillary nerve, V2 division); and mental nerve (sensory terminal branch of the mandibular nerve, V3 division). Block of the frontal nerve is useful for lower forehead and upper eyelid surgery; block of the infraorbital nerve is commonly used in neonates, infants, and older children undergoing cleft lip repair

or surgeries of the lower eyelid, the upper lip, and the median cheek; block of the mental nerve is used in procedures involving the lower lip, skin of the chin, and the incisive and canine teeth.¹³ In our cases, we use the block of the infraorbital nerve and mental nerve before the incision and drainage of the mandibular abscess was performed.

Although never had been done before, trigeminal nerve block had shown promising result therefore shows its potential to be an alternative anesthesia method in difficult airway cases. Intubation in GA increases the risks of laryngospasms, postoperative sore throat, airway displacement, aspiration or laryngotracheal soiling.¹⁴ Trigeminal nerve block is preferred than general anesthesia because its correlation with better postoperative outcomes such as reduced nausea, lower incidence of blood clots, less postoperative pain, less blood loss, and lower infection rate. Using this technique also reduce the amount of opioid and analgesic agents necessary during and after the procedure.¹⁵

Conclusion

In conclusion, the utilization of superficial trigeminal nerve block in our case proved to be a beneficial alternative to general anesthesia, particularly in context of submandibular abscess management. This regional anesthesia technique offering advantages in terms of airway management and reducing the associated risks of intubation and postoperative management including intensive postoperative care and complications. This technique's versatility, demonstrated in various surgical contexts, suggests its potential as a valuable alternative to general anesthesia in diverse medical procedures including submandibular abscess management.

Acknowledgement

State if any of the authors has a conflict of interests. If there is none please state: The authors report no conflict of interests.

References

1. Jacques N, Karoutsos S, Marais L, Nathan-Denizot N. Quality of life after trigeminal nerve block in refractory trigeminal neuralgia: A retrospective cohort study and literature review. *Journal of International Medical Research*. 2022;50(10):030006052211320. doi:10.1177/03000605221132027
2. Han KR, Kim C, Chae YJ, Kim DW. Efficacy and safety of high concentration lidocaine for trigeminal nerve

block in patients with trigeminal neuralgia. *Int J Clin Pract*. 2007;62(2):248-254. doi:10.1111/j.1742-1241.2007.01568.x

3. Kanthan Rk. The use of superficial cervical plexus block in oral and maxillofacial surgical practice as an alternative to general anesthesia in selective cases. *Ann Maxillofac Surg*. 2016;6(1):4. doi:10.4103/2231-0746.186120
4. Srirompotong S, Art-smart T. Ludwig's angina: a clinical review. *European Archives of Oto-Rhino-Laryngology*. 2003;260(7):401-403. doi:10.1007/s00405-003-0588-9
5. Boscolo-Rizzo P, Marchiori C, Montolli F, Vaglia A, Da Mosto MC. Deep Neck Infections: A Constant Challenge. *ORL*. 2006;68(5):259-265. doi:10.1159/000093095
6. Boscolo-Rizzo P, Da Mosto MC. Submandibular space infection: a potentially lethal infection. *International Journal of Infectious Diseases*. 2009;13(3):327-333. doi:10.1016/j.ijid.2008.07.007
7. Karkos PD, Leong SC, Beer H, Apostolidou MT, Panarese A. Challenging airways in deep neck space infections. *Am J Otolaryngol*. 2007;28(6):415-418. doi:10.1016/j.amjoto.2006.10.012
8. Bhat MT, Hegde H V., Santhosh MCB, Rao RP. Orbital exenteration under trigeminal block: An innovative method of regional anesthesia. *Saudi J Anaesth*. 2013;7(4):470-473. doi:10.4103/1658-354X.121051
9. Danilo Jankovic. *Regional Nerve Blocks and Nfi It Rat Ion Therapy Textbook and Color Atlas*. 3rd ed. (Taylor S, ed.). Blackwell Publishing; 2004.
10. Stalfors J, Adielsson A, Ebenfelt A, Nethander G, Westin T. Deep neck space infections remain a surgical challenge. a study of 72 patients. *Acta Otolaryngol*. 2004;124(10):1191-1196. doi:10.1080/00016480410017864
11. Kumar A, Sinha C, Kumar A, Kumari P, Mukul SK. Ultrasound-guided trigeminal nerve block and its comparison with conventional analgesics in patients undergoing faciomaxillary surgery: Randomised control trial. *Indian J Anaesth*. 2018;62(11):871-875. doi:10.4103/ija.IJA_256_18
12. Saripalli RRR, Kasaraneni S, Yadavilli SS, Alluri LSC. Superficial Cervical Plexus Block in Selective Cases of Oral and Maxillofacial Surgery as an Alternative to General Anesthesia: A Case Presentation. *Cureus*. Published online January 18, 2022. doi:10.7759/cureus.21371
13. Hadzic A. *HADZIC'S TEXTBOOK OF REGIONAL ANESTHESIA AND ACUTE PAIN MANAGEMENT.*; 2017.
14. Xu R, Lian Y, Li WX. Airway Complications during and after General Anesthesia: A Comparison, Systematic Review and Meta-Analysis of Using Flexible Laryngeal Mask Airways and Endotracheal Tubes. *PLoS One*. 2016;11(7):e0158137. doi:10.1371/journal.pone.0158137
15. Breen P, Park KW. General anesthesia versus regional anesthesia. *Int Anesthesiol Clin*. 2002;40(1):61-71. doi:10.1097/00004311-200201000-00006