

The Relationship Between Measurements Of Medial Tibial Plateau Depth And Femoral Notch (Notch Width & Shape) On Genu Mri And The Severity Of The Isolated Anterior Cruciate Ligament Tear : Cross Sectional Study At Tertiary Referral Hospital Dr. Moewardi General Hospital & Prof. Soeharso Orthopedic Hospital

Amelia Tjandra Irawan¹, Anistyaning Wahyu Adhie², Yutrisa Sasti³, Yudhi Lillah⁴

¹²³⁴Department of Radiology, Faculty of Medicine, Sebelas Maret University, Dr Moewardi Hospital, Surakarta, Indonesia

*Corresponding: ameliatjandrairawan@gmail.com

Abstract

Background: The knee is a complex joint, composed of ligament components, one of which is the Anterior cruciate ligament which functions as a knee stabilizer. ACL injury is the most common ligament injury in the knee joint. Anatomical factors are one of the factors that predict the severity of an ACL tear. Medial Tibial Plateau Depth and Femoral Notch are one of the influencing factors. Genu MRI examination plays an important role in assessing these factors regarding the severity of an Isolated ACL tear.

Objective: To determine the relationship between measurements of Medial Tibial Plateau Depth and Femoral Notch (Notch Width & Shape) on MRI genu with the severity of Isolated Anterior Cruciate Ligament Tear at Dr. Moewardi Hospital Surakarta and Prof. Soeharso Orthopedic Hospital Surakarta

Method: Quantitative analytical research with a cross-sectional design was conducted from May to June 2023. The research sample was patients who underwent a Knee MRI examination with clinical Isolated ACL Tear in the period 1 January 2021 to 30 June 2023. Patients were assessed for the severity of the ACL tear and measurements of the Medial Tibial Plateau Depth and Notch Width and the shape of the Femoral Notch Os Femur

Results: Medial tibial plateau depth on MRI Genu was positively correlated with the severity of isolated ACL tear (p value <0.001 and r correlation value of 0.943). Femoral Notch Shape, especially the A shape, has a relationship with the severity of isolated ACL tear (p value = 0.036 (p < 0.05) and r value = 0.274). Meanwhile, the relationship between femoral notch width on MRI Genu and the degree of isolated ACL tear is not significant because the p value obtained is 0.484 (p>0.05)

Conclusion: Medial Tibial Plateau Depth and Femoral Notch Shape on MRI Genu have a relationship with the Severity of Isolated

Anterior Cruciate Ligament Tear, whereas Femoral Notch Width has no relationship

Keywords: *Isolated ACL Tear, Medial Tibial Plateau Depth, Femoral Notch, MRI Genu*

Introduction

The knee is one of the most complex and crucial joints in the human body. The number of extreme sports that put a load on the knee makes the knee joint one of the joints that most frequently experience trauma (Wijayasurya and Setiadi, 2021). One of the ligaments that serves as a stabilizer of the knee and prevents anterior-posterior translation of the tibia is the cruciate ligament.

The anterior cruciate ligament is said to be one of the most important knee stabilizers that prevents translation of the anterior tibia above the femur. ACL injuries are currently the most common ligament injuries to the knee joint. The number of incidences is 1 in 3,500 individuals annually (Ahmed et al., 2017). Although various studies say the overall incidence of ACL injury is common in men due to higher participation in sports, the relative risk in women is said to be 2-8x greater (Arundale et al., 2022).

Tears in the ACL can occur during exercise and are usually caused by sudden stops or changes in direction during running, jumping, and landing. ACL injuries can occur in isolation or involve multiligaments. Sports such as skiing, ice hockey, gymnastics, or the presence of automotive accidents, especially those involving motorcycles, are common causes of knee ligament disorders. Sudden heavy loads without falls or contact, such as the slowing of a running athlete can also cause injury to ligaments (Ahmed et al., 2017).

An isolated ACL injury is an injury that only involves the ACL, but does not involve other ligaments around the knee. This injury is quite disabling and takes a lot of time to recover and rehabilitate despite surgery. In addition, people with these injuries tend to end up with articular wear conditions that increase over time and end up with early post-traumatic arthritis even with the best surgery (Jagadeesh et al., 2021).

There are three main ACL tear mechanisms: direct contact, indirect contact, and noncontact. Direct contact injury occurs when a person or object strikes the knee directly, exerting valgus force on the knee, which can result not only in injury to the ACL, but also to other knee structures, called O'Donoghue's triad. Indirect contact injury occurs when a person or object strikes a body part other than the knee itself, causing excessive force to be transferred through the knee (such as a direct blow to the thigh, translations of the posterior femur with respect to the tibia), resulting in ACL injury. Non-contact injury occurs when the deceleration or change of direction (axis) of the force on the knee results in rotational motion in which the tibia rotates externally on the treading foot, as in skiers, during a fall where the inner edge of the ski is stuck into the ice, resulting in the knee in a state of external and valgus rotation

Risk factors for ACL tear can be divided into two main categories: intrinsic and extrinsic. Intrinsic factors include those that are innate from the individual and usually cannot be modified. These include factors such as anatomical factors (Notch parameters, posterior tibial slope, medial tibial plateau depth, etc.), neuromuscular factors, genetic factors, hormonal environment and cognitive function. Extrinsic factors are factors that surround and can include the level and intensity of play or activity, surface conditions and play environment, as well as equipment used (Jagadeesh et al., 2021).

Many intrinsic factors can be predictors of someone experiencing a tear in the ACL, one of which is anatomical factors (Jagadeesh et al., 2021). One of these risk factors is the depth in the hollow of the subchondral bone in the aspect of the medial compartment of the tibia known as the Medial Tibial Plateau and the shape and width of the intercondylar notch of the os femur or known as the Femoral notch. (Fahim et al., 2021). The measurement of these three factors, obtained through radiological imaging based on previous research, has a relationship with the severity of tears in the ACL.

There are many modalities for diagnosing an ACL tear, but a good anamnesis and physical examination are the key steps (Ahmed et al., 2017). Magnetic resonance imaging (MRI) is a sensitive, non-invasive and accurate modality in detecting knee soft tissue injuries. MRI is a reliable method to confirm a clinical diagnosis and reveal ligament tears (Ahmed et al., 2017; Chien et al., 2020). MRI is an important diagnostic modality in determining the degree and incidence of ACL tears, although its accuracy varies. Diagnostic and therapeutic arthroscopy is still the gold standard in ACL tear cases, especially in dubious cases (Shah et al., 2021)

The diagnosis of an ACL tear should not be delayed so that further treatment can be planned immediately. Establishing the diagnosis and determining the severity of ACL tears on MRI images will help clinicians determine the best treatment for patients and recommendations for arthroscopy and surgical needs in patients (Dar et al., 2022). Management of ACL injuries is chosen based on the extent of the injury, the patient's desire to exercise in the future, and his working and social conditions. Treatment can be conservative or rehabilitative, ligament reconstruction or operative treatment (Filbay and Grindem, 2019; Wijayasurya and Setiadi, 2021).

By this time, there has not been many research on the relationship of anatomical intrinsic factors such as Medial Tibial Plateau Depth and the shape and width of the intercondylar notch of the os femur known as Femoral notch on Genu MRI examination on the severity of Isolated ACL Tear, particularly at Dr. Moewardi Hospital. This study aims to determine the relationship between *medial tibial plateau depth* and *femoral notch* measurements (*notch width* & *shape*) on genu MRI with the severity of *isolated anterior cruciate ligament tear* at dr. Moewardi Regional General Hospital, Surakarta and as an adjunct at Prof. Dr. R. Soeharso Surakarta Orthopedic Hospital.

Materials and Methods

This study is an analytical quantitative study with a cross-sectional design in isolated ACL tear patients undergoing knee MRI examination. The study was conducted in the Radiology Installation of Dr. Moewardi Regional Hospital Surakarta and Prof. Soeharso Hospital Surakarta. This study was conducted in collaboration with the Orthopedic Sub-Specialty Hip Knee Reconstruction, Radiology Installation and Medical Record of Orthopaedic Hospital Prof. Dr. R. Soeharso, Surakarta and Dr. Moewardi

Regional Hospital Surakarta in May - July 2023. The samples of this study were all patients who underwent knee MRI examination with clinically proven isolated ACL tear in knee arthroscopy at the Radiology Installation of Dr. Moewardi Regional Hospital Surakarta and Prof. Soeharso Hospital Surakarta between January 1, 2021 to June 30, 2023 who met the inclusion criteria and exclusion criteria.

The inclusion criteria in this study were patients who had undergone knee MRI examination with clinical knee injury, diagnosed with isolated ACL tear on MRI examination and proven in knee arthroscopy and had complete knee MRI data and medical records at Dr. Moewardi Regional Hospital Surakarta and Prof. Soeharso Hospital Surakarta. The exclusion criteria in this study were patients with multiligament injury findings, patients with previous ACL injuries, patients with bone fractures in the knee area and patients with congenital deformities in the knee. The independent variables in this study were Medial Tibial Plateau Depth and Notch Width measurements and the shape of the Femoral Notch (Notch Width & Shape) Os Femur in patients with Isolated ACL Tear. The dependent variable of the patients of this study was the Degree of Severity of Isolated ACL Tear on Genu MRI examination.

Sampling was carried out using the total sampling method. Patient demographic data such as age, sex, body mass index and location of injury were taken. The patient's bio data were recorded on the research questionnaire form. Each subject was examined by Genu MRI and assessed the severity degree of Isolated ACL tears as well as the measurement of Medial Tibial Plateau Depth and Femoral Notch (Notch Width & shape) which was assessed on a soft file Digital Imaging and Communication in Medicine (DICOM) Magnetic Resonance Imaging (MRI) using a DICOM viewer.

The results of this study would be analyzed using the Kolmogorov-Smirnov normality test to determine whether the data distribution was normally distributed or not. P value > 0.05 if the data is normally distributed. Normally distributed numerical data will be analyzed using the *One-Way Anova* test and whereas non-normally distributed data using the *Kruskal Wallis test*. Subsequently, the correlation of the dependent variable with the independent variable was carried out with the Spearman Rank correlation test. Device data was

analyzed by Statistical Package for Social Science 25.0 (SPSS) software for Windows. The study began after an ethical clearance and research permit were issued from the Health and Medical Research Ethics Commission of Faculty of Medicine UNS / RSUD dr. Moewardi Surakarta and Prof. Dr. R. Soeharso Orthopedic Hospital Surakarta. The data were taken from the medical record without mentioning the patient's identity.

Results of the Study

This study was an analytical quantitative study with a cross-sectional design in isolated ACL tear patients undergoing knee MRI examination. The study was conducted in the Radiology Installation of Dr. Moewardi Regional Hospital Surakarta and Prof. Soeharso Hospital Surakarta. This study involved 40 patients who underwent a Knee MRI examination with clinical isolated ACL tear at Prof. Soeharso Surakarta Hospital between January 1, 2021 to June 30, 2023. Data were obtained from medical records and MRI examination results of patients' knees at the Radiology Installation of Dr. Moewardi Regional Hospital Surakarta and Prof. Soeharso Hospital Surakarta in May - July 2023. Sampling was adjusted to predetermined inclusion and exclusion criteria.

Based on table 1, it is discovered that most of the isolated ACL tear patients were male with a total of 32 patients (80%), while the rest were female with a total of 8 patients (20%). The age of patients was distributed from the age of 1-20 years to the elderly > 60 years with the youngest age was 16 years old and the oldest age was 65 years old. For the age range of 1-20 years, there were 8 patients (20%), the age group of 21-40 years there were 25 patients (62.5%), the age group of 41-60 years there were 5 patients (12.5%) and the age group of > 60 years there were 2 patients (4%). The location of rupture was mostly on the right and left legs, with a total of 21 patients (52.5%) and 19 patients (47.5%) respectively. The cause of the incidence of isolated ACL patients was due to sports injuries, with a total of 40 patients (100%). The most common found of femoral notch was Ω which was found in 22 patients (55%), followed by A shape found in 14 patients (35%) and U shape found in 4 patients (10%).

Table 1. Patient Demographic Data

Characteristics	N	(%)
Age		
- 1 – 20 years	8 (40)	20

- 21 – 40 years	25 (40)	62.5
- 41 – 60 years	5 (40)	12.5
- > 60 years	2 (40)	4
Sex		
1. Male	32 (40)	80
2. Female	8 (40)	20
Ruptur ACL		
1. Severe	14 (40)	35
2. Moderate	14 (40)	35
3. Mild	12 (40)	30
Location		
1. Right	21 (40)	52.5
2. Left	19 (40)	47.5
Notch Shape		
1. Ω	22 (40)	55
2. A	14 (40)	35
3. U	4 (40)	10
Trauma Mechanism		
Sport Trauma	40 (40)	100

Table 2 presents a description of patient characteristics based on the degree of isolated ACL tear, namely mild, moderate and severe. Based on patient age, the oldest average age of patients with moderate isolated ACL tear was 33.9 ± 14.9 years, while in the youngest age of patients with mild isolated ACL tear was 28.0 ± 9.8 years, almost similar with patients with severe isolated ACL tear (29.6 ± 8.5 years). However, when the patients' ages were compared to each other, the results were insignificantly different, which was indicated by the result of p value of One-Way Anova test of 0.395 ($p > 0.05$). The distribution of patients according to sex and degree of isolated ACL tear was also insignificantly different, indicated by the Fisher Exact test result of 0.226 ($p > 0.05$). Male patients were more dominant at all levels/degrees of isolated ACL tear than female patients.

The distribution of patients' BMI also did not show significant differences according to the degree of isolated ACL tear. Half of patients (50%) of mild, moderate, or severe isolated ACL tears, respectively had a normal BMI ($p = 0.963$). The degree of isolated ACL tear was also insignificantly different ($p = 0.536$), the mild degree was mostly found (64.3%) in dekstra, the moderate degree was found more in sinistra (58.3%) however the severe degree was equally found between dekstra and sinistra (50.0% each). Based on the results of the analysis, it can be stated that the patients' characteristics were homogeneous or not a confounding factor of the relationship between the independent and dependent variables studied, which was the relationship between the medial tibial plateau depth and femoral notch on Genu MRI with the degree of isolated ACL tear.

Table 2. Patients' characteristics based on the degree of isolated ACL tear: mild, moderate and severe

Patients' Characteristics	Degree of Isolated ACL tear			p-value
	Mild (n=14)	Moderate (n=12)	Severe(n=14)	
Age, Year, mean± SD	28,0±9,8	33,9±14,9	29,6±8,5	0,395*
Male, %	64,3	91, 7	85,7	0,228^
BMI, %				
- Underweight	21,4	16,7	7,1	0,963^
- Normal	50,0	50,0	50,0	
- Overweight	14,3	16,7	28,6	
- Obese	14,3	16,7	14,3	
Dextra, %	64,3	41,7	50,0	0,536^
Sample Origin				
- Dr. Moewardi Regional Hospital	57,1	66,7	28,6	0,162^
- Prof. Soeharso Orthopedic	42,9	33,3	71,4	

Hospital

The analysis of medial tibial plateau depth and femoral notch images on Genu MRI according to the degree of isolated ACL tear was carried out using the Spearman Rank correlation test due to the non-normal distribution of the three variables data. The results can be seen in table 3. Table 3 shows that the relationship between medial tibial plateau depth on Genu MRI and the degree of isolated ACL tear was significant as evidenced by $p = 0.800$ and approaching 1.000 . Meanwhile, the relationship between the femoral notch on Genu MRI and the degree of isolated ACL was insignificant because the p value obtained was 0.484 ($p > 0.05$), with a negative relationship direction which means that there is a tendency that a

high femoral notch value is associated with a heavier degree of isolated ACL tear.

To prove whether medial tibial plateau depth and femoral notch on Genu MRI were predictors of isolated ACL tear degrees a multiple linear regression analysis was conducted as seen in table 4. The medial tibial plateau depth and femoral notch values on Genu MRI were tested together, and it was discovered that only the medial tibial plateau depth proved to be a predictor of the degree of isolated ACL tear because it had a value of $p < 0.001$ and a regression coefficient value of 0.953 ; while the femoral notch on Genu MRI was not a predictor factor of isolated ACL tear severity because the p value obtained was 0.119 ($p > 0.05$).

Table 3. Results of analysis of the relationship between medial tibial plateau depth and femoral notch on Genu MRI with isolated ACL tear degree

<i>isolated ACL tear degree</i>		
Spearman's rho	r	0,943**
	p	<0,001
	N	40
	r	0,114
	p	0,484
	N	40

Table 4. Results of analysis of medial tibial plateau depth and femoral notch on Genu MRI as a predictor of the isolated ACL tear degree

Variable	Regression Coefficient	p-value
MTPD (mm)	0,953	<0,001
<u>Femoral notch (cm)</u>	<u>0,077</u>	<u>0,119</u>

Table 5 shows that the average medial tibial plateau depth tended to decrease with the high severity of *the isolated ACL tear*, and the results of the comparison of the average medial tibial plateau depth based on the three degrees of severity of the isolated ACL tear after being tested with One Way Anova obtained a value of $p < 0.001$ indicating that there was a significant difference in the average medial tibial plateau depth across degrees of severity *isolated ACL tear* which can also be interpreted that medial tibial plateau depth is related to the severity of *isolated ACL tear*. In this section, One Way Anova was used as a test because the results of the analysis of the distribution of medial

tibial plateau depth data according to the severity of the isolated ACL tear was normal.

Conversely, in the femoral notch variable, the analysis used was non-parametric, which was Kruskal Wallis because the distribution of data obtained for the femoral notch at the severity of isolated ACL tear was abnormal. Based on the Kruskal Wallis test, it was discovered that the average femoral notch in the severity of isolated ACL tear of severe (2.05 ± 0.20 mm), medium (1.95 ± 0.17 mm) and mild (2.01 ± 0.26 mm) were insignificantly different indicated by a p value of 0.427 ($p > 0.05$) so it was stated that the femoral notch was not related to the severity of mild isolated ACL tear.

Table 5. Results of the analysis of relationship between medial tibial plateau depth and femoral notch on Genu MRI with isolated ACL tear degree

Result of Genu MRI	Isolated ACL tear Degree			<i>p-value</i>
	Severe (n=14)	Moderate (n=12)	Mild (n=14)	
<i>Medial tibial plateau depth, mean ± SD, mm</i>	2,31±0,27	3,80±0,39	5,45±0,58	<0,001*
<i>Femoral notch, mean ± SD, cm</i>	2,05±0,20	1,95±0,17	2,01±0,26	0,037 [#]

Table 6 shows the One-Way Anova test in *post hoc Tamhane* conducted because the variance of medial tibial plateau depth data was inhomogeneous. It was discovered that the ratios of medial tibial plateau depth

between two degrees of severity of isolated ACL tear were all significant ($p < 0.001$) which can also be interpreted that low medial tibial plateau depth is associated with high degrees of severity of isolated ACL tear.

Table 6. Results of comparative analysis of medial tibial plateau depth on Genu MRI between two Degrees of severity of isolated ACL tear

Degree of severity of isolated ACL tear	<i>p-value</i>
Mild vs Moderate	<0,001
Mild vs Severe	<0,001
Moderate vs Severe	<0,001

Table 7 shows the morphometric distribution of MRI femoral *notch* shape with severity of *Isolated Anterior Cruciate Ligament Tear*. 1st, 2nd and 3rd degree of ACL tear. The Ω shape was present in the majority of patients, it was 20 out of 40 patients (50%), followed by A shape in 16 patients out of 40 patients (40%) and U shape in 4 patients (10%). Ω shapes are more proportions in grade III with a total of 9 patients compared to the number of patients with femoral notch A and U shapes,

Ω shapes also have more proportions in grade II with 8 patients each compared to A shape and U shape in grade II. In grade I, femoral notch A and Ω shapes have the same number, namely 4 patients and 5 patients. Statistical test results obtained a value of $r = 0.274$; $p = 0.036$ ($p < 0.05$) which means that there is a significant relationship between the shape of the *notch* and the severity of the *Isolated Anterior Cruciate Ligament Tear* with the strength of the weak category relationship.

Table 7. Notch Shape Distribution by the Severity Degree of Isolated ACL Tear

Notch Shape	Severity Degree of Isolated ACL tear			Total
	Degree I	Degree II	Degree III	
A shape	4 (10 %)	6 (15 %)	4 (10%)	14 (35%)
Ω shape	5 (12,5%)	8 (20 %)	9 (22,5 %)	22 (55%)
U shape	3 (7,5%)	0(0%)	1 (2,5%)	4 (10%)
Total	12 (30%)	14 (35%)	14 (35%)	40 (100%)

Discussion

Tears or injuries to the anterior cruciate ligament are the most common injuries with an incidence of 13.7 (95% CI 9.6 to 19.5) per 100,000 person-years. (Ponkilainen et al., 2022) The incidence of ACL tears has doubled over the past two decades, despite efforts by researchers and

clinicians to reduce the risk of the incidence. According to Clínica Centro de Madrid, most ACL injuries are caused by exercises involving motions of spinning, decelerating, or impact (Arundale et al., 2022; Casado et al., 2019). A tear in the ACL will cause the knee to be unable to work optimally while the ACL is the main stabilizer for anterior translation of the tibia (Priono et al., 2018).

The total patients included in this study were 40 patients with isolated Anterior Cruciate Ligament tear and undergoing knee Magnetic Resonance Imaging at the Radiology Installation of Dr. Moewardi Regional Hospital Surakarta and Prof. Soeharso Hospital Surakarta between January 1, 2021 to June 31, 2023 who had met the inclusion and exclusion criteria. Demographic data of patients with isolated ACL tears are listed in a characteristic table where sex, average age, location of affected knees, body mass index, and injury mechanism are also displayed in each patient.

The number of male patients was 32 patients (80%) with only 8 female patients (20%). Male patients mostly experienced grade III tears of 45% while women mostly experienced grade I tears with 12.5%. The majority of patients are male according to the reference stated by Larruskain *et al.*, (2019) where contact injuries are more common in men, although in term of incidence rate the ligament injuries can be more common in women for reasons of biomechanical differences and neuromuscular control (Casado *et al.*, 2019; Larruskain *et al.*, 2018). Men are said to have more frequent ACL tears due to the *narrower* intercondylaris femoral *notch* and larger α angle. (Fernández-Jaén *et al.*, 2015).

The age range of patients in the study was the oldest at 33.9 ± 14.9 years, while in patients with *mild isolated ACL tear* the youngest was at 28.0 ± 9.8 years. Fabricant and Kocher (2016) published a demographic of ACL tears in pediatric patients and young adults where the incidence in this age group is increasing. Age is an important consideration where growth disorders can occur in this age group. (Fabricant and Kocher, 2016). The locations of ACL tears on the right and left sides were 21 and 19 patients, respectively. The literature states there is no significant difference in the incidence of ACL tears with age or the side of the knee affected (Fernández-Jaén *et al.*, 2015).

The majority BMI was *normoweight* of 21 patients out of a total of 40 patients or about 52.5%. Patients with overweight criteria were found in 19 patients out of a total of 40 patients, which was about 47.5%.

This is in contrast to a study that has been published by Kizilgov *et al.* (2019) which examined the effect of the combination of BMI and *tibial slope angle* and discovered that BMI provided the greatest effect compared to other parameters studied on the risk of ACL tear. (Kızılgöz *et al.*, 2019). Another literature by Huang *et al.* (2019) states that there were no significant differences in the categories of BMI, age, sex, injury mechanism and side of the knee affected according to the severity of the ACL tear (Huang *et al.*, 2019). Another study that also examined the demographics of patients in the form of age, sex, side of the knee affected, height, weight and BMI of patients showed no significant correlation of this demographic factor with the risk of ACL injury (Whitney *et al.*, 2014).

Assessment of the degree of ACL tear is performed primarily using sagittal cut knee MRI with T1SE sequence and PDTSEFS 200% magnification to assess the fibers of the ACL and the degree of tearing. Grade I if there is a partial tear $< 50\%$ thickness/substance ACL or *low grade tear*. Grade II if the partial tear $> 50\%$ thickness/substance of the ACL where there are still fibers from the ACL but clouded or the substance is torn *high grade*. Grade III when there is a total tear of the thickness/substance of the ACL or said to be a total rupture until there are no more visible ACL fibers running transversely from the sagittal cut. (Dar *et al.*, 2022; Hong *et al.*, 2003)

Medial Tibial Plateau Depth is the depth of subchondral bone concavity in the aspect of the medial compartment of the tibia. The measurement of the depth of the concavity in the medial aspect of the tibia is done by drawing a line connecting the the superior and inferior apex of the tibial plateau in the same cut in which the Medial Tibial Slope is measured. The measurement is done by making a line parallel to this line then drawn tangent to the lowest point of the concavity, which represents the lowest boundary of the subchondral bone. The perpendicular distance between the two lines is then measured and used to represent the measurement of *Medial Tibial Plateau Depth*. (Jagadeesh *et al.*, 2021)

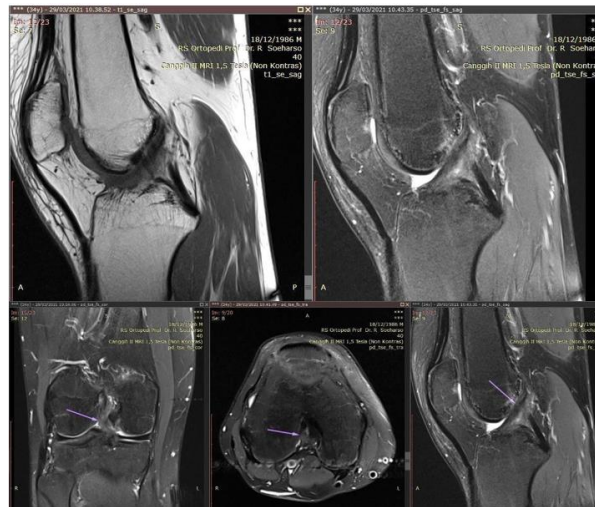

Figure 1. Example of a grade I ACL tear with a partial tear of <50% ACL thickness/substance on MRI of the knee, sagittal cut T1SE and PDTSEFS sequence. Bottom image, MRI coronal, axial and sagittal cut PDRSEFS sequence.

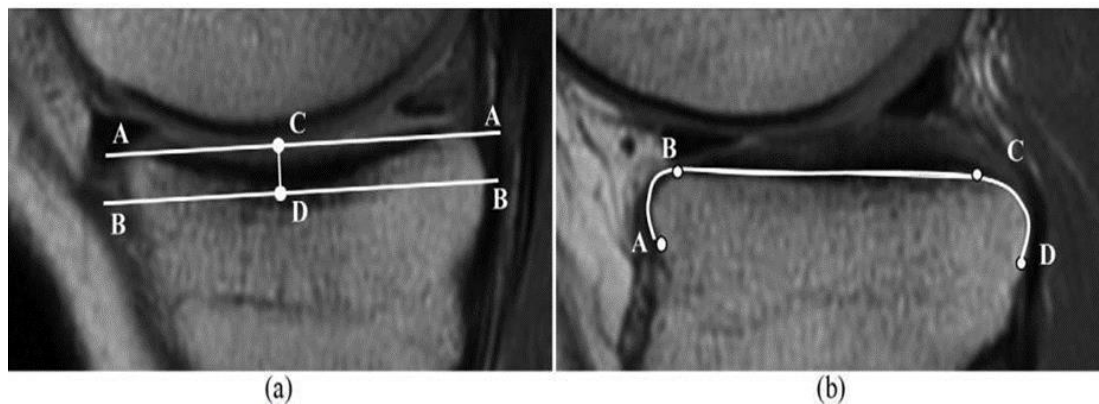


Figure 2. a: A magnetic resonance image illustrating the method used to determine the *Medial Tibial Plateau Depth* in the area near the articulation region. b: Although the lateral aspect of the *Tibial Plateau* (represented by ABCD) as a whole, the articulation region (BC region) is fairly flat in most aspects

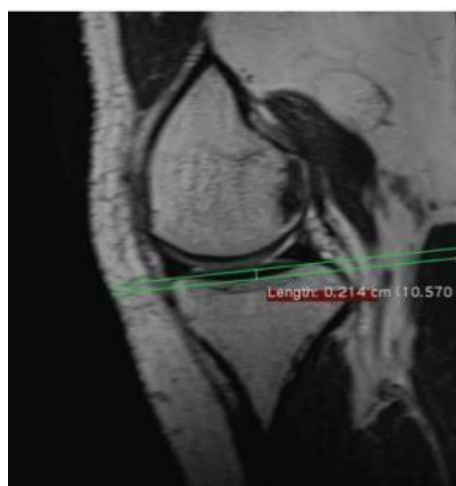


Figure 3. *Medial Tibial Plateau Depth Measurement*

Medial Tibial Plateau Depth measurement has a theory that the shallower the depth of the Medial Tibial Plateau will cause a greater risk of tearing in the ACL. This is in accordance with the study conducted where the relationship between medial tibial plateau depth on Genu MRI with the degree of isolated ACL tear was significant as evidenced by $p < 0.001$ and a

correlation value (r) of 0.943. This correlation value means that the medial tibial plateau depth on Genu MRI is positively related to the degree of isolated ACL tear, the lower the medial tibial plateau depth value, the heavier the degree of isolated ACL tear. The correlation value also indicates that the strength of the relationship between medial tibial plateau depth on Genu MRI and the

degree of isolated ACL tear was very strong because the r value obtained was >0.800 and close to 1.000. Medial Tibial Plateau Depth proved to be a predictor of the degree of isolated ACL tear because it had a value of $p<0.001$ and a regression coefficient value of 0.953. One of the intrinsic factors, namely anatomical factors, is the shape of the intercondylar notch and notch width (NW) as risk factors for ACL tear. The role of the narrow intercondylar notch with the ACL tear was first recognized by Palmer in 1938.

Various notch parameters e.g.; notch shape and notch width (NW) have been identified as risk factors. (Basukala et al., 2020).

The shape of the intercondylar notch of femur is divided into 3 forms namely A, U (*inverted U*) and Ω (Omega) where A shape is the notch shape where $NWJ > NWP$, U (*inverted U*) when $NWJ = NWP$, and Ω (Omega) When $NWJ < NWP$. (Ashwini et al., 2018; Fahim et al., 2021)

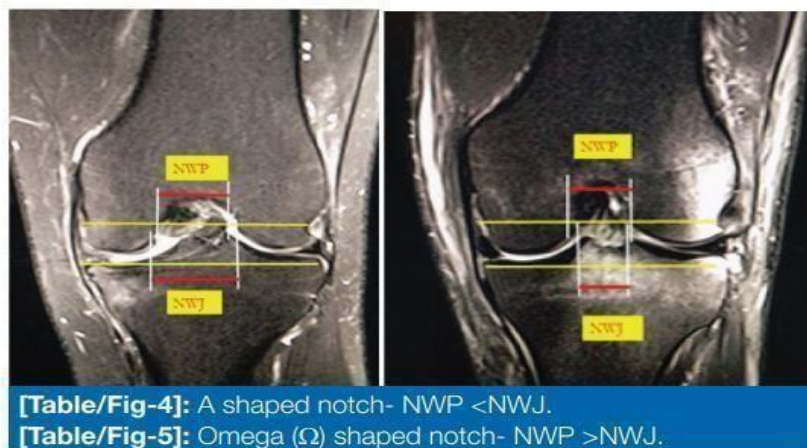


Figure 4. NWP and NWJ on MRI Coronal T2Fatsat. A shape – $NWP < NWJ$, Ω shape - $NWP > NWJ$. (Ashwini et al., 2018)

Notch shape is a statistically significant correlated variable with the severity of isolated ACL tears. The results of the statistical test obtained a value of $r = 0.274$; $p=0.036$ ($p<0.05$) which means that there was a significant relationship between *Notch Shape* and the severity degree of *Isolated Anterior Cruciate Ligament Tear* with the weak category of relationship strength. The most notch shape was Ω with 22 patients (55%), followed by A shape in 14 patients (35%) and U shape with 4 patients (10%).

The severity degree of the heaviest isolated ACL tear, degree III, was dominated by notch shape A and Ω which were 4 and 9 (10% and 22.5%, respectively) compared to the U-shape which was 1 patient (2.5%).

Ashwini et al (2018) in their research discover that the Ω form with a low NWI value is a predisposing factor to ACL tears while Fahim et al (2021) show that the A shape with a narrow notch width and a smaller index has a greater incidence of ACL tears. This is in accordance with previous references which say that A and Ω shapes are a greater risk factor for ACL injury while U shape is the 'best' shape which is not a risk factor for ACL tear (Ashwini et al., 2018; Basukala et al., 2020; Fahim et al., 2021).

Notch width (NW) is identified as the measurement of the nearest distance of the medial and lateral femoral condyles/middle part of the knee joint. NW can be measured using MRI axial cut on the T2 sequence of the knee. (Jagadeesh et al., 2021).

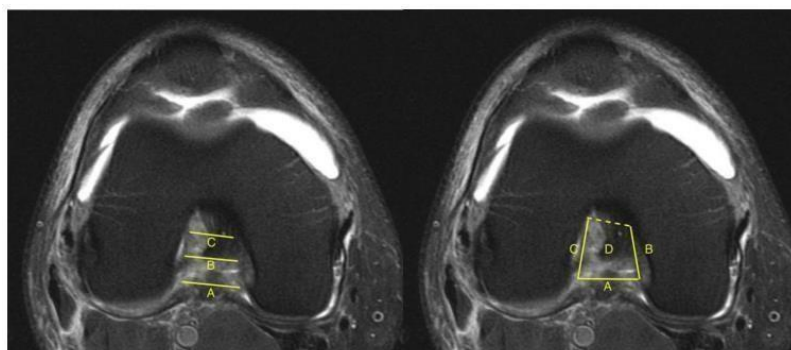


Figure 5. Example of measuring *notch width* on MRI. Measurement on T2 sequence axial cut from left knee (A) notch width measurement at base, (B) *mid height*, (C) *apex*. Right

image, (A) notch width base, (B) medial, (C) lateral wall height, (D) area. (Vaswani et al., 2020).

The relationship between the femoral notch on Genu MRI and the degree of isolated ACL tear is not significant because the p value obtained was 0.484 ($p > 0.05$), but the direction of the relationship shown was positive which means that there was a tendency that the high femoral notch value was related to the high degree of isolated ACL tear. Femoral Notch Width on Genu MRI was not a predictor of isolated ACL tear severity because the p value obtained was 0.119 ($p > 0.05$). A research conducted by Priono et al (2018) also reveals that notch width does not have a significant effect on the increase in the incidence of ACL injuries. Several other studies such as Yellin et al (2021), Fahim et al (2021), Basukala et al (2019), Ashwini et al (2018) show that stenosis in the notch greatly affects the risk of ACL injury. (Ashwini et al., 2018; Basukala et al., 2020; Fahim et al., 2021; Yellin et al., 2021). Gupta et al (2021) discovered cases with narrower notch widths in ACL injury patients compared with the uninjured population (20.24 ± 2.68 mm vs. 22.04 ± 2.56 mm) and concluded that narrower notch width and smaller ACL volume increase the risk of ACL tears in athletes. (Gupta et al., 2022).

Conclusion

There is a relationship between Medial Tibial Plateau Depth measurement and Femoral Notch shape on genu MRI with the severity degree of Isolated Anterior Cruciate Ligament Tear, however on Femoral Width Notch measurement on genu MRI no relationship was obtained. In this study, Medial Tibial Plateau Depth MRI morphometry has a significant relationship with the severity degree of Anterior Cruciate Ligament (ACL) tears, shallower depths have a greater risk of isolated ACL tear severity. Femoral Notch MRI morphometry that has a significant relationship to the severity of isolated Anterior Cruciate Ligament (ACL) tears is the notch shape or the shape intercondylaris os femur notch, where the A and Ω shapes are the dominant shape found in the degree of severity of isolated ACL tear grade III. Femoral Notch Width at the joint line (NWJ) level showed no statistically significant association with ACL tear severity degree.

References

Ahmed, A., Razzaque, M.A., Kaleem, M., Zaman, A.U., Akram, R., Javed, S., 2017. Diagnostic accuracy of magnetic resonance imaging in detecting anterior cruciate ligament injuries. Med.J.Indones. 26, 218–23.

<https://doi.org/10.13181/mji.v26i3.1873>

Arundale, A.J.H., Silvers-Granelli, H.J., Myklebust, G., 2022. ACL injury prevention: Where have we come from and where are we going? J. Orthop. Res. Off. Publ. Orthop. Res. Soc. 40, 43–54.
<https://doi.org/10.1002/jor.25058>

Ashwini, T., Aditi, J., Ashok, A.K., 2018. MRI Correlation of Anterior Cruciate Ligament Injuries with Femoral Intercondylar Notch, Posterior Tibial Slopes and Medial Tibial Plateau Depth in the Indian Population. International J. Anat. Radiol. Surg. Vol-7(3), RO01–RO06. <https://doi.org/DOI:10.7860/IJARS/2018/36086:2397>

Basukala, B., Joshi, A., Pradhan, I., 2020. The Effect of the Intercondylar Notch Shape and Notch Width Index on Anterior Cruciate Ligament Injuries. J. Nepal Health Res. Council. 17, 532–536.
<https://doi.org/10.33314/jnhrc.v17i4.1858>

Casado, M., Seijas, R., Perez-Bellmunt, A., Navarro Uribe, R., Ragazzi, P., Alvarez, P., 2019. International Journal of Sports and Exercise Medicine Epidemiology of Primary Anterior Cruciate Ligament Ruptures in Men and Women. Int. J. Sports Exerc. Med. 5. <https://doi.org/10.23937/2469-5718/1510114>

Chien, A., Weaver, J.S., Kinne, E., Omar, I., 2020. Magnetic resonance imaging of the knee. Pol. J. Radiol. 85, e509–e531.
https://doi.org/10.5114/pjr.2020.99415_44

Dar, A.J., John, A., Ashraf, S., Faridi, T.A., Zahid, S., Nazir, A.B., 2022. MRI Diagnosis and Grading of Anterior Cruciate Ligament Injuries. Pak. Biomed. J. 341–345.

Diermeier, T., Rothrauff, B.B., Engebretsen, L., Lynch, A.D., Ayeni, O.R., Paterno, M.V., Xerogeanes, J.W., Fu, F.H., Karlsson, J., Musahl, V., Svantesson, E., Hamrin Senorski, E., Rauer, T., Meredith, S.J., Panther Symposium ACL Treatment Consensus Group, 2020. Treatment after anterior cruciate ligament injury: Panther Symposium ACL Treatment Consensus Group. Knee Surg. Sports Traumatol. Arthrosc. Off. J. ESSKA 28, 2390–2402.
<https://doi.org/10.1007/s00167-020-06012-6>

Fahim, S.M., Dhawan, T., Jagadeesh, N., Ashwathnarayan, Y.P., 2021. The relationship of anterior cruciate ligament injuries with MRI based calculation of femoral notch width, notch width index, notch shape - A randomized control study. J. Clin. Orthop. Trauma 17, 5–10.
<https://doi.org/10.1016/j.jcot.2021.01.006>